

Original

One anastomosis gastric bypass: a simple, safe and efficient surgical procedure for treating morbid obesity

M. García-Caballero* and M. Carbajo**

*Department of Surgery. University Malaga. **Department of Surgery. Campo Grande Hospital. Valladolid. España.

Abstract

The One Anastomosis Gastric Bypass has been developed from the Mini Gastric Bypass procedure as originally described by Robert Rutledge. The modification of the original procedure consists of making a latero-lateral gastro-jejunal anastomosis instead of a termino-lateral anastomosis, as is carried out as described in the original procedure.

The rationale for these changes is to try to reduce exposure of the gastric mucosa to biliopancreatic secretions because of their potentially carcinogenic effects with longer term exposure, which is the major criticism of the original technique. If we fix the jejunal loop to the gastric pouch some centimetres up to the gastro-jejunal anastomosis the biliopancreatic secretions have less possibility of coming into the gastric cavity (gravity force). Furthermore, if the anastomosis is latero-lateral this possibility is reduced even more. In addition, the intestinal loop reinforces the staple line against disruption, and also the gastric pouch against dilatation.

(*Nutr Hosp* 2004, 19:372-375)

Key words: *Mini Gastric Bypass. Gastric pouch against dilatation.*

Introduction

When surgeons needed to develop a procedure for effecting weight loss, they mimicked clinical situations where weight loss occurred. Therefore, the initial concept was to use a surgical procedure which provoked a short bowel syndrome- (jejuno-ileal bypass) which is the clinical situation with

Correspondencia: Prof. M. García-Caballero.
Department of Surgery.
University Malaga.
Facultad de Medicina.
29080 Málaga.
E-mail: gcaballe@uma.es

Recibido: 10-VIII-2004.
Aceptado: 11-X-2004.

EL BYPASS GÁSTRICO DE UNA ANASTÓMOSIS: UN PROCEDIMIENTO SIMPLE, SEGURO Y EFICAZ PARA TRATAR LA OBESIDAD MÓRBIDA

Resumen

El Bypass Gástrico de Una Anastomosis se ha desarrollado a partir del Mini Bypass Gástrico descrito por Robert Rutledge. La modificación del procedimiento original consiste en hacer una anastomosis latero-lateral en lugar de termino-lateral como se hace en la técnica original.

Este cambio intenta reducir la exposición de la mucosa gástrica a la secreción bilio-pancreática, evitando así el posible efecto carcinogénico de la exposición crónica que constituye la más importante crítica del procedimiento original. Al fijar el asa de yeyuno a la nueva bolsa gástrica unos centímetros por encima de la anastomosis gastro-yeyunal, la secreción bilio-pancreática tiene menos posibilidades de entrar en la cavidad gástrica (fuerza de gravedad). Al ser la anastomosis latero-lateral esta posibilidad se reduce aún más. Además, el asa de yeyuno refuerza la línea de grapas contra su interrupción y previene la posible dilatación de la bolsa gástrica.

(*Nutr Hosp* 2004, 19:372-375)

Palabras clave: *Mini Gastric Bypass. Dilatación bolsa gástrica.*

most weight loss. However, the dramatic metabolic consequences^{1,2} indicated the necessity to develop less aggressive, but still efficient, surgical procedures to bring about a loss of weight. The different approaches that have been developed during the years aimed to minimise the operative trauma and optimise the long term nutritional and metabolic consequences. As a result, procedures such as vertical banded gastroplasty³ and gastric banding⁴ were introduced into clinical practice. These procedures were associated with a limited weight loss but, importantly, there were undesirable chronic side effects and complications also occurred. For these reasons, other techniques have been developed including mixed restrictive and low malabsorptive procedures such as the Roux Y gastric bypass^{5,6}, or

high malabsorptive as biliopancreatic bypass^{7,8} and duodenal switch operations^{9,10}. However, these are also associated with more morbidity and significant chronic nutritional and metabolic complications.

In 1997 Robert Rutledge took again as a starting point the Billroth II gastric operation which has been carried out previously by others¹¹ and shown in a million patients to provoke loss of weight. He adapted the original operation as described by Billroth and applied laparoscopic techniques to its further development. Indeed, excellent results for the first 1,274 patients who were treated using this technique have been reported¹².

Some surgeons were concerned that patients who were subjected to a Billroth II procedure (as well as those undergoing other procedures for peptic ulcer disease such as vagotomy) had a risk of 0.8% of developing gastric cancer within 25 years of the operation and have criticized the procedure¹³. However, this finding has not been consistent and others have failed to demonstrate this link¹⁴.

We have studied in depth the advantages and disadvantages of the Mini Gastric Bypass procedure, and finally we have concluded that the new procedure had many differences when compared with the original Billroth II, or other gastric bypasses based on it. Furthermore, these differences could explain the results reported by Rutledge. The new procedure has, in our opinion, clear advantages over other surgical operations in use at present for treating morbid obesity.

However, in order to reduce the contact of biliopancreatic secretions with the gastric mucosa, and also for reducing the possibility of gastric pouch dilatation, we have introduced some modifications into the Mini Gastric Bypass as originally described by Robert Rutledge. These will be described below.

The technique

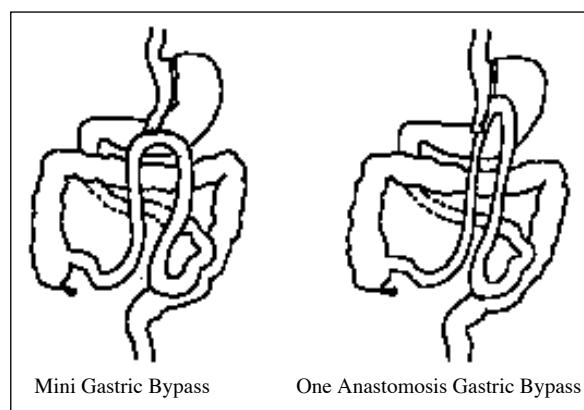


Fig. 1. —Schematic representation of the original Mini Gastric Bypass and the One Anastomosis Gastric Bypass.

The laparoscopic One Anastomosis Gastric Bypass is similar to the Mini Gastric Bypass¹². The differences are illustrated in figure 1. As can be observed, the gastro-jejunal anastomosis is performed latero-laterally instead of termino-laterally.

Detailed description of the surgical technique

The procedure commences by inducing a pneumoperitoneum through the left subcostal space (figure 2).

The first trocar (10 mm) is introduced through the middle point of the line between the xiphoid and umbilicus, and through which we introduce the camera. The second trocar (12 mm) is positioned 5 cm to the right side of the first, and at the same level. Then, the third trocar (12 mm) is inserted 5 cm to the left side of the first one, and again at the same level. The fourth and smallest trocar (5 mm) is inserted into the right flank at the lower edge of the liver (internal view control) and serves to allow the introduction of the liver retractor. Finally, the fifth trocar (5 mm) is positioned in a left sub-costal position, and is approximately 10 cm away from the second trocar (see diagram).

Once the operation field has been prepared, the esophago-gastric junction is identified. The first step consists of preparing a hole in the gastric fundus at the esophago-gastric junction. This allows the access to the posterior wall of the stomach which will facilitate the later creation of the gastric pouch.

Then, we move to the lesser curvature and identify a point at the “crow’s foot” level. As close as possible to the gastric serosa, we start to make a hole in order to gain access to the posterior wall of the stomach. Once we come to the posterior stomach wall we introduce a 45 mm EndoGhia, 3.5 mm cartridge (Tyco®) and transect the stomach horizontally. Then, we commence the vertical stomach transection which progresses until the esophageal-gastric junction has been reached, using a 1 cm nasogastric tube placed in the lesser curvature of the stomach, as a guide. We use two or three 60 mm EndoGhia, 3.5 mm cartridges (Tyco®) to complete the transaction of the stomach. An additional 30 or 45 mm EndoGhia, 3.5 mm cartridge (Tyco®), is sometimes needed.

After making the gastric pouch, we insert a sixth trocar (5 mm) at McBurney’s point. We proceed identifying the angle of Treitz. Then we measure approximately 2 m jejunum distally from this point. Once this point has been localized, a 10 cm long and 0.5 cm wide rubber band is passed around the small intestine. With the help of a “grasp”, we approximate the jejunal loop to the gastric pouch.

When both are in position side by side, we fix the jejunum to the staple line of the gastric pouch with 6 to 10 sutures using an Endostitch (Tyco®). When both are fixed, we anastomose the gastric pouch to

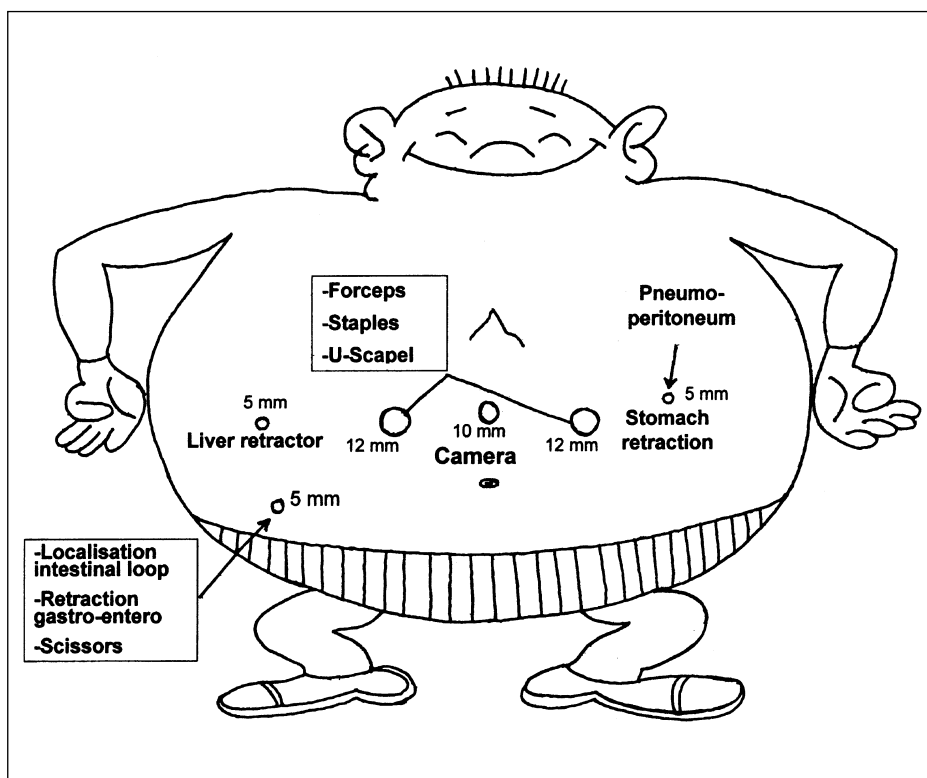


Fig. 2.—Schema of the port sites and the instruments used through each of them.

the jejunal loop using a 30 mm EndoGhia, 3.5 mm cartridge (Tyco®) from which we introduce only a part (the length of the anastomosis is between 15 and 20 mm). The gastric and jejunal holes are closed using 4 to 6 sutures. For checking if the anastomosis is securely closed, we put it under saline and inject 60 to 100 ml of air through the nasogastric tube and there should be no air bubbles seen to be escaping from the anastomosis. Finally we seal the anastomosis by using 2 ml of fibrin glue (Tissucol®). We place a suture between the intestinal loop and the gastric antrum so as to “unload” the anastomosis trying to avoid any tension on it. An omentoplasty is always performed using omentum to cover the gastro-jejunal anastomosis. Finally, a soft drain is always positioned below the liver.

Twenty four hours after the operation we perform a radiological contrast study (oral gastrograffin) to check that the pouch and anastomosis is not leaking. If the result is normal we start as a three hours liquids tolerance checking before the patient goes home.

Comments

The surgery to treat morbid obesity should follow, in our opinion, the principle of “the simplest procedure that permits enough weight loss with less short and long-term complications and better quality of life”.

The One Anastomosis Gastric Bypass is a minimally traumatic procedure for the patient. The techni-

que is carried out in the same way always, and independently of the weight of the patient. However, the results are always comparable: the patients lose around 80% of their pre-operative excess body weight during the next two years (most of this occurs during the first year). This has been shown from the results of the first 200 first patients we have operated on.

The most important changes that occurs in this operation when compared with the classical Roux-en-Y Gastric Bypass (RYGB) are: 1) it is not necessary to interrupt the physiological intestinal transit; 2) hence, we do not produce a hole in the mesentery which avoid the possibility of developing around 8% post-operative intestinal obstruction¹²; 3) the latero-lateral gastrojejunal anastomosis using linear staples also avoids the 10% risk of gastrojejunal strictures occurring after RYGB; 4) finally, we also avoid the luminal nutrients having contact with the intestinal jejunal mucosa without prior mixture with the biliopancreatic secretion. This would not happen under physiological conditions (luminal nutrients are always together with biliopancreatic secretion as happens in our bypass procedure) which has been proven to provoke mucosal hypotrophy and bacterial translocation¹³.

The most important change when compared with the original Mini Gastric Bypass as described by Robert Rutledge¹⁴, is the type of anastomosis. Our modification of the original procedure tries to minimise the contact and chronic effect of the biliopancreatic secretions on gastric mucosa, which is an important reason for per-

forming this otherwise very efficient procedure. At the same time, we cover the distal part of the staple line and protect it against disruption and dilatation.

To achieve that, we fix the jejunal loop to the stomach pouch some centimetres over the anastomosis (see figure 1) so that the biliopancreatic secretion fall down some centimetres to the 15 to 20 mm latero-lateral gastro-jejunal anastomosis. The effect of the gravity force and the lateral connection with the stomach (together with the entry of gastric secretion and the alimentary bolus), minimizes the contact of the biliopancreatic secretions with the gastric mucosa (as demonstrated during the clinical evolution in our first 200 patients where there hasn't been symptomatic episodes of gastric irritation).

In summary, the One Anastomosis Gastric Bypass is, as is also the original Mini Gastric Bypass, a quick to perform and low risk procedure with minimal post-operative complications experienced by the patients. Because of the minimum trauma associated with this procedure, the postoperative recovery period is in the region of 24 hours. The patients recover quickly and can resume their activities within two to three days. The weight loss that occurs subsequently, is not accompanied by nutritional or metabolic disturbances. This weight loss is maintained for more than two years (as demonstrated by the long-term follow-up of Mini Gastric Bypass patients) since the size of the gastric pouch and the site of intestinal anastomosis with the intestine (approximately 2 m from the angle of Treitz) is the same as in this procedure. The only change compared with Mini Gastric Bypass, the latero-lateral gastro-jejunal anastomosis, and results in conditions that diminish the contact and hence the chronic effect of biliopancreatic secretions on the gastric mucosa. Also, by using fibrin glue sealant on the one and only anastomosis that is performed, the risk of anastomotic leakage or fistula formation is reduced as low as possible.

References

1. Deitel M: Jejuno-colic and jejuno-ileal bypass: an historical perspective. In: *Surgery for the Morbidly Obese Patient*. M. Deitel, editor. Philadelphia. Lea & Febiger 1989, pp. 81-90.
2. Deitel M, Shahi B, Anand PK, Deitel FH, Cardinell DL: Long-term outcome in a series of jejuno-ileal bypass patients. *Obes Surg* 1993; 3:247-
3. Mason EE: Vertical banded gastroplasty for morbid obesity. *Arch Surg* 1982, 117:701-6.
4. Belachew M, Legrand M, Jacquet N: Laparoscopic adjustable silicone gastric banding in the treatment of morbid obesity: a preliminary report. *Surg Endosc* 1994, 8:1354-6.
5. Torres JC, Oca CF, Garrison RN: Gastric bypass Roux-en-Y gastro-jejunostomy from the lesser curvature. *South Med J* 1983, 76:1217-21.
6. De la Torre RA, Scott JS: Laparoscopic Roux-en-Y gastric bypass: a totally intra-abdominal approach — technique and preliminary report. *Obes Surg* 1999, 9:492-8.
7. Scopinaro N, Gianetta E, Civalleri D, Bonalumi U, Bachi V: Bilio-pancreatic bypass for obesity: II. Initial experience in man. *Br J Surg* 1979, 66:618-20.
8. Paiva D, Bernardes L, Suretti L: Laparoscopic diversion for the treatment of morbid obesity: initial experience. *Obes Surg* 2000, 11:619-22.
9. Hess DS, Hess DW: Biliopancreatic diversion with a duodenal switch. *Obes Surg* 1998, 8:267-82.
10. Feng JJ, Gagner M: Laparoscopic biliopancreatic diversion with duodenal switch. *Semin Laparosc Surg* 2002, 9:125-9.
11. Mason EE, Ito C: Gastric bypass in obesity. *Surg Clin North Am* 1967, 47:1345-51.
12. Pappasavvas PK, Caushaj PF, McCormick JT, Quinlin RF, Hayetian FD, Maurer J, Kelly JJ, Gagne DJ: Laparoscopic management of complications following laparoscopic Roux-en-Y gastric bypass for morbid obesity. *Surg Endosc* 2003, 17:610-4.
13. García-Caballero M: Adaptación intestinal: Factores tróficos y mecanismos celulares. *Cir Esp* 1995, 58:52-60.
14. Rutledge R: The mini-gastric bypass: experience with the first 1,274 cases. *Obes Surg* 2001, 11:276-80.
15. Bekavac-Beslin M, Halkic N: Gastric stump cancer after stomach resection due to peptic disease. *Chir Ital* 1996, 48:9-12.
16. Bassily R, Smallwood RA, Crotty B: Risk of gastric cancer is not increased after partial gastrectomy. *J Gastroenterol Hepatol* 2000, 15:762-5.